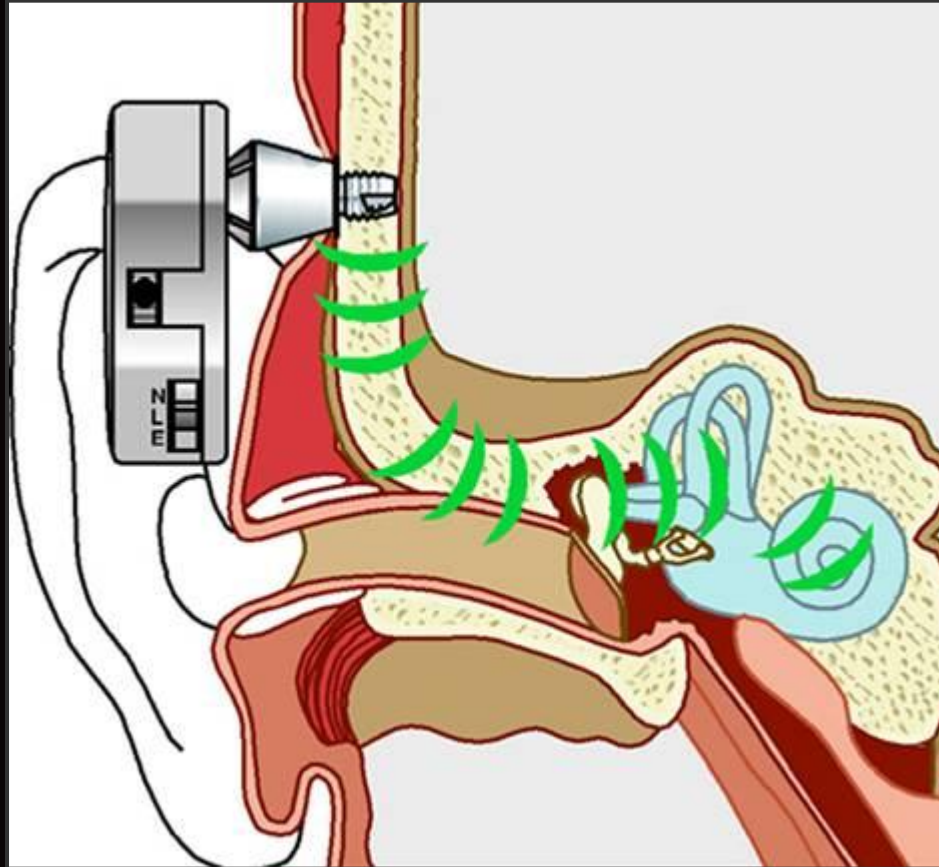

Baha Softband Case Studies: Managing
Conductive and Mixed Hearing Loss in
Craniofacial and Syndromic Individuals

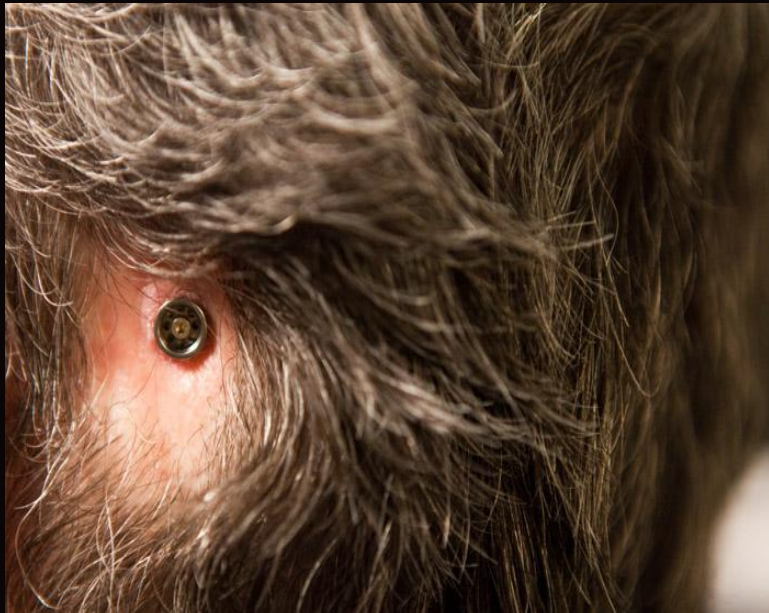George Cire, Au.D

Lisa Christensen, Au.D

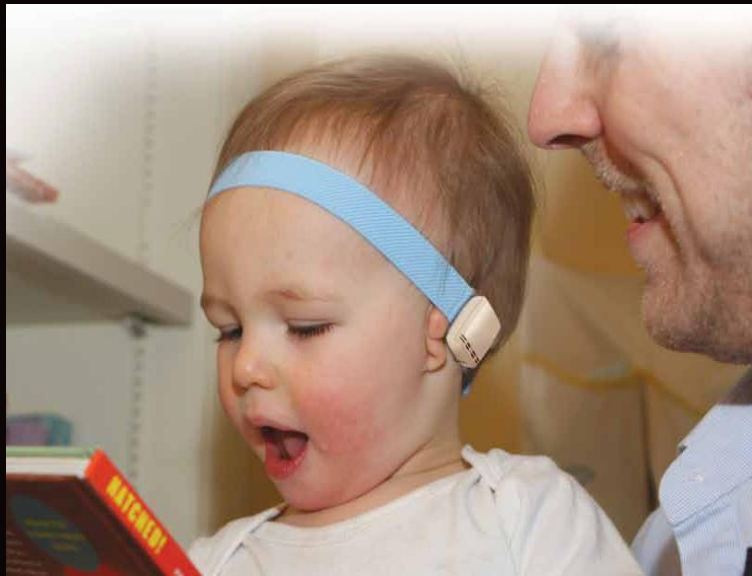Direct Bone Conduction with Baha



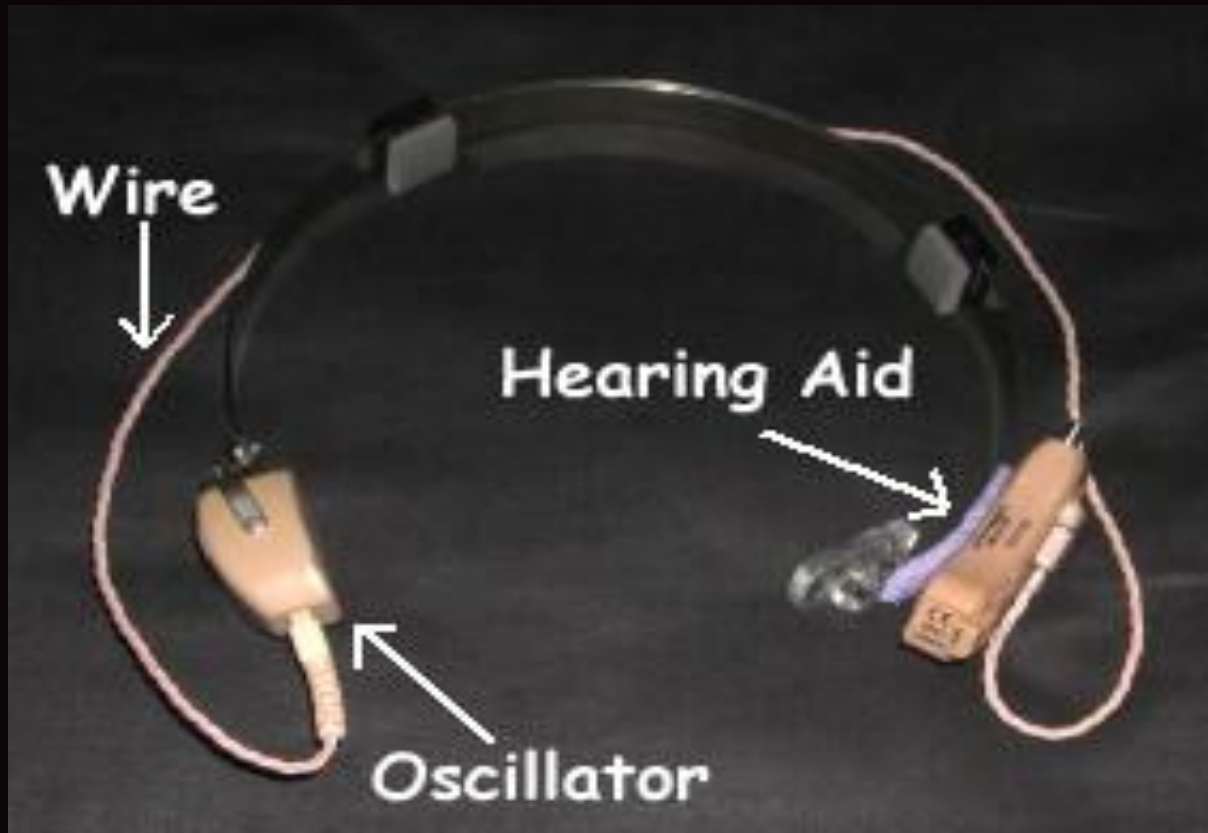
Baha Osseointegrated Implant



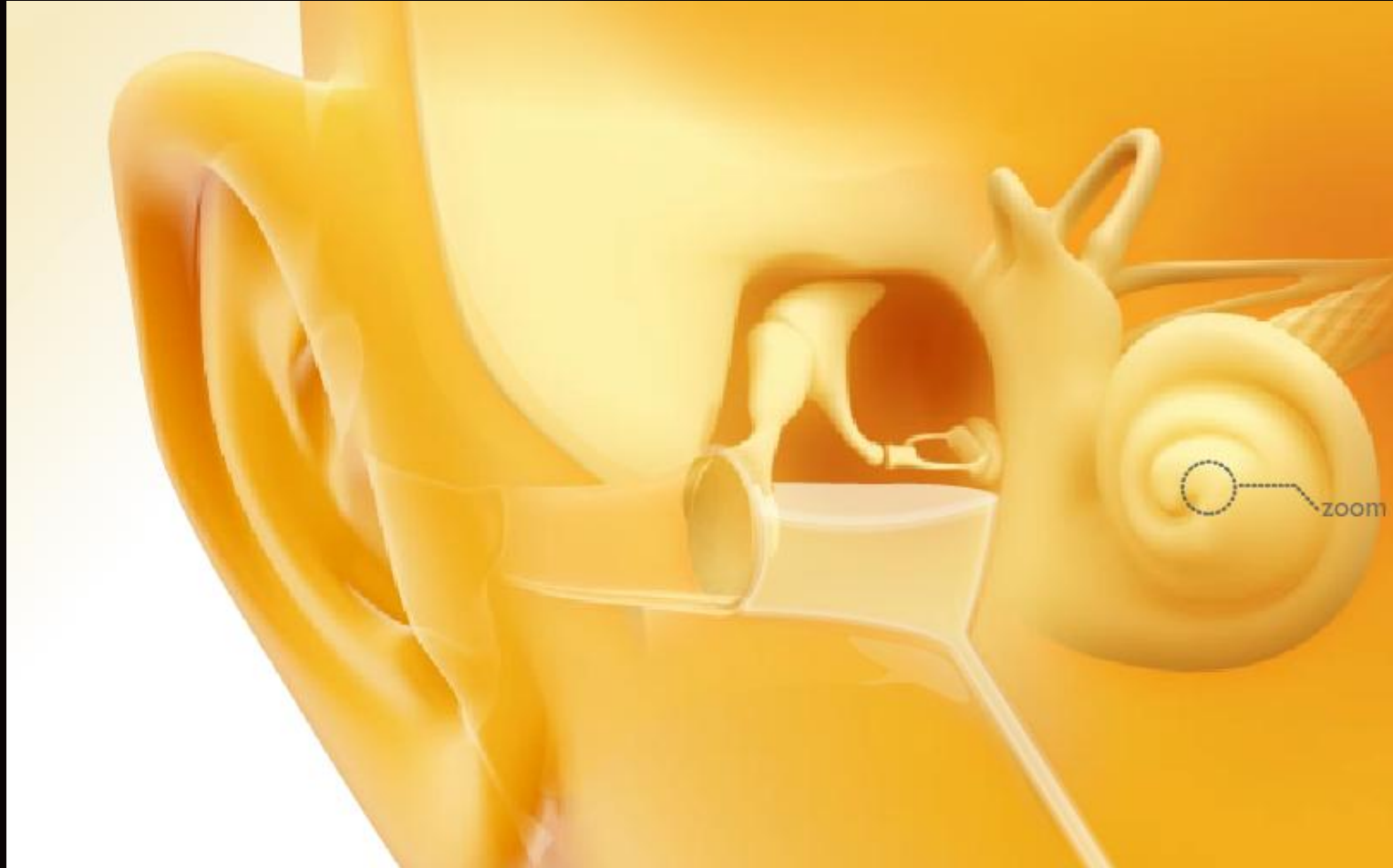
Baha Softband



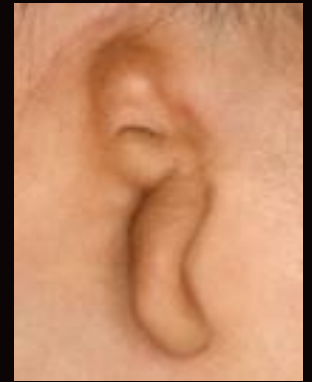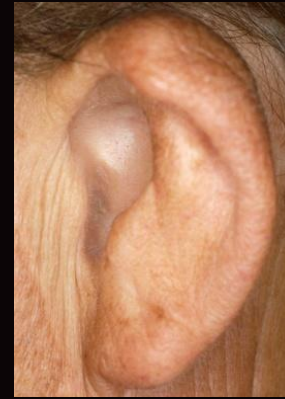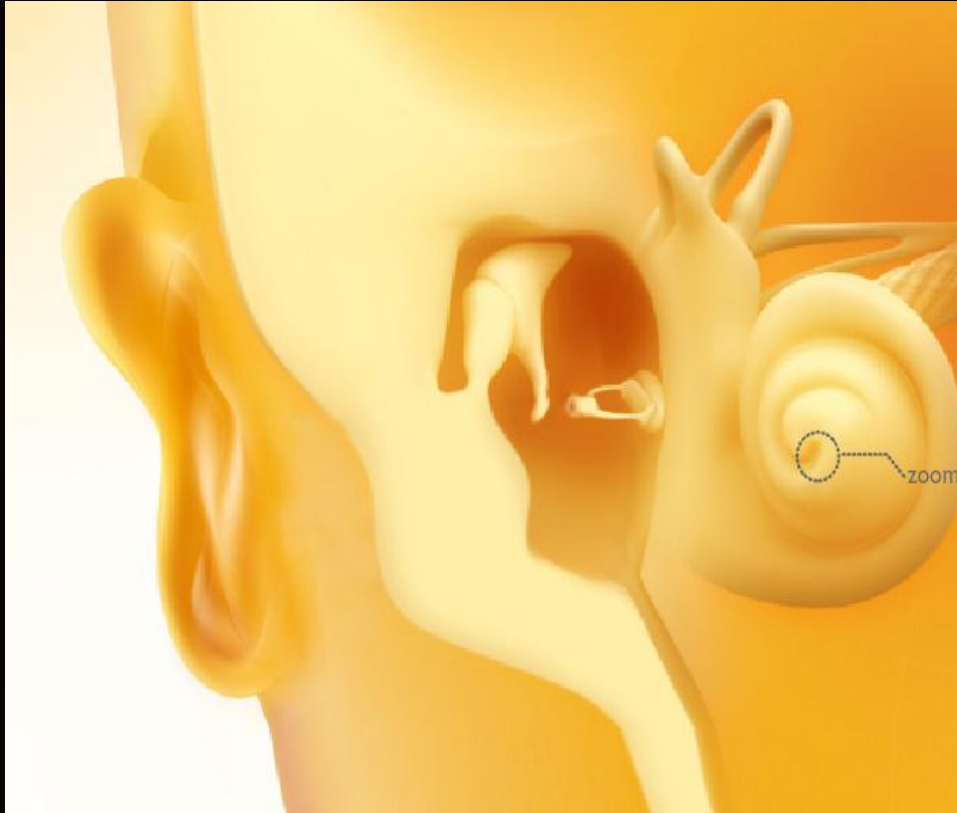Traditional Bone Conduction Hearing Aid



Normal anatomy with Otitis Media



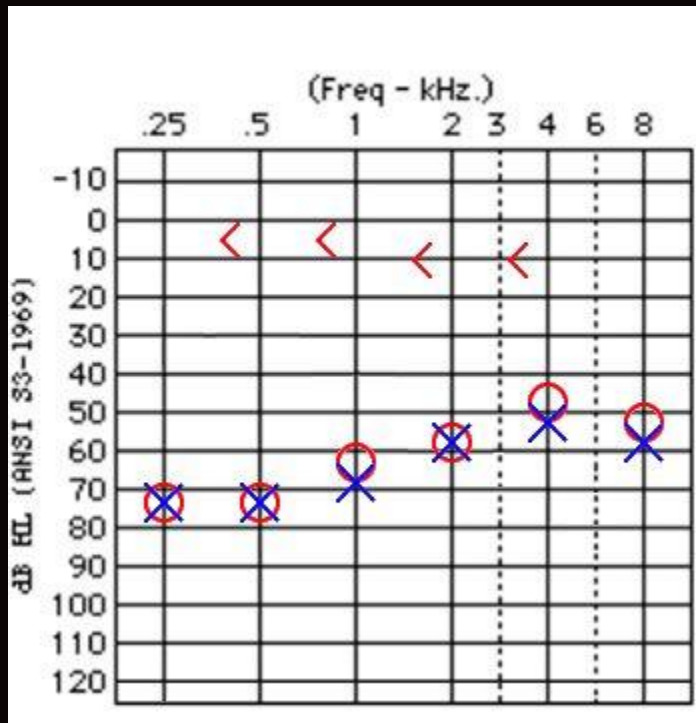
Congenital atresia



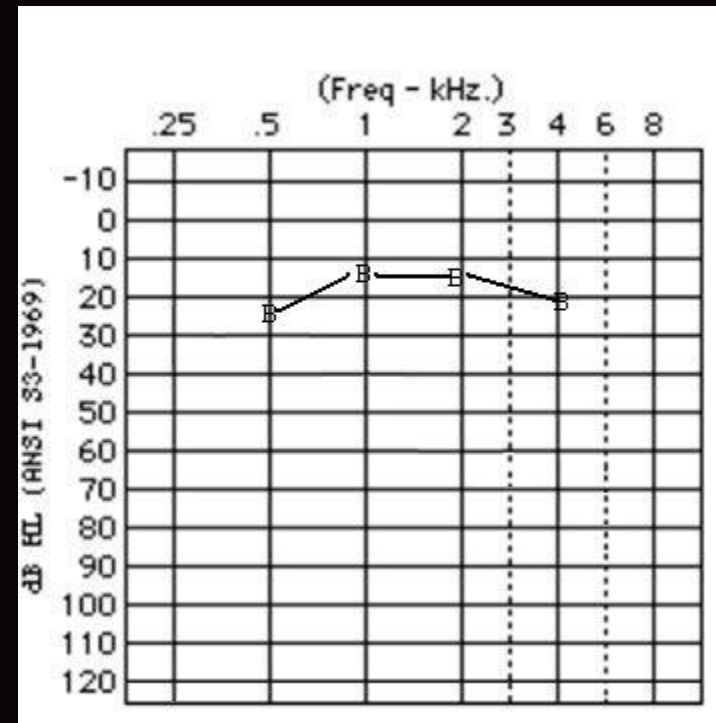
William

- DOB: 2-27-2005
- Bilateral atresia
- ABR: 3-28-05
- Fit with Baha Compact on Softband 5-20-2005

William



Unaided

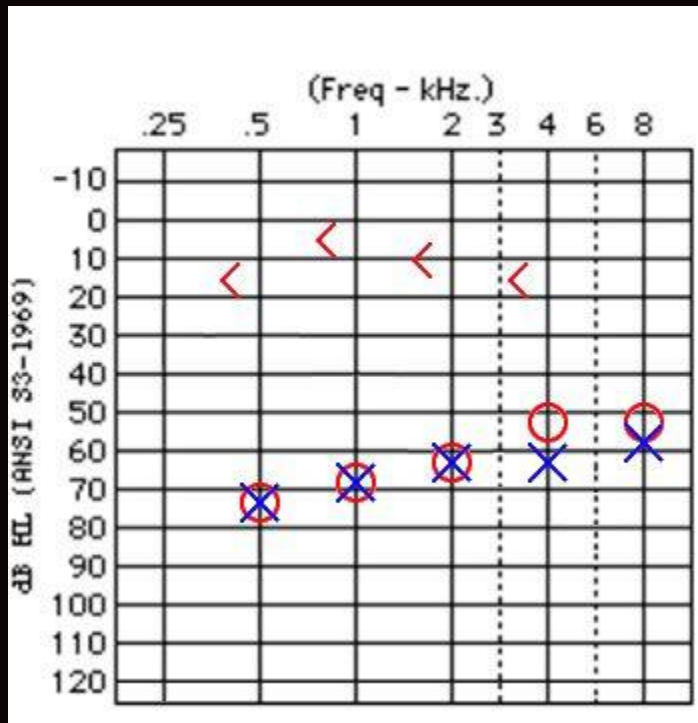


Aided

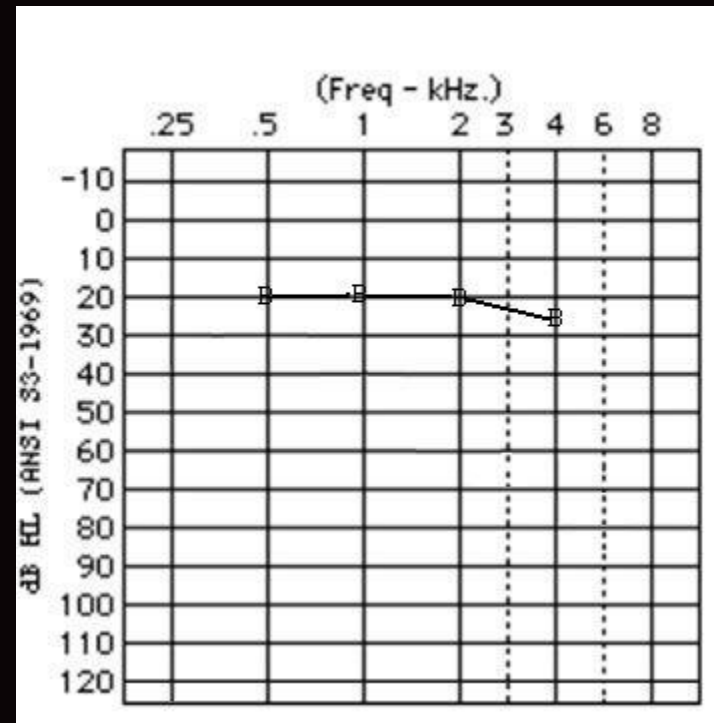
Evan

- DOB: 3-14-2007
- Failed NBHS
- Failed re-screen at ACH
- ABR at age 3 months
- Fit with Baha loaner at 5 months
- Funding accomplished and permanent Baha fit at 11 months

Evan



Unaided

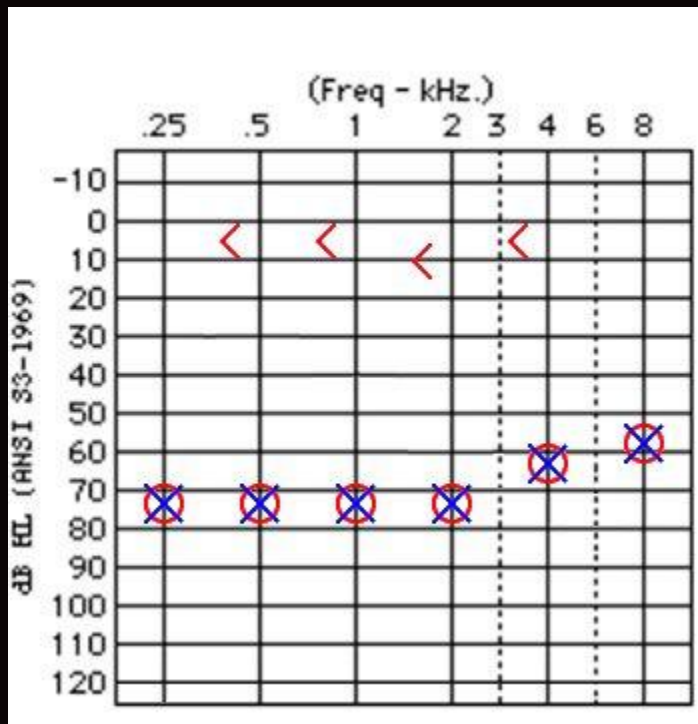


Aided

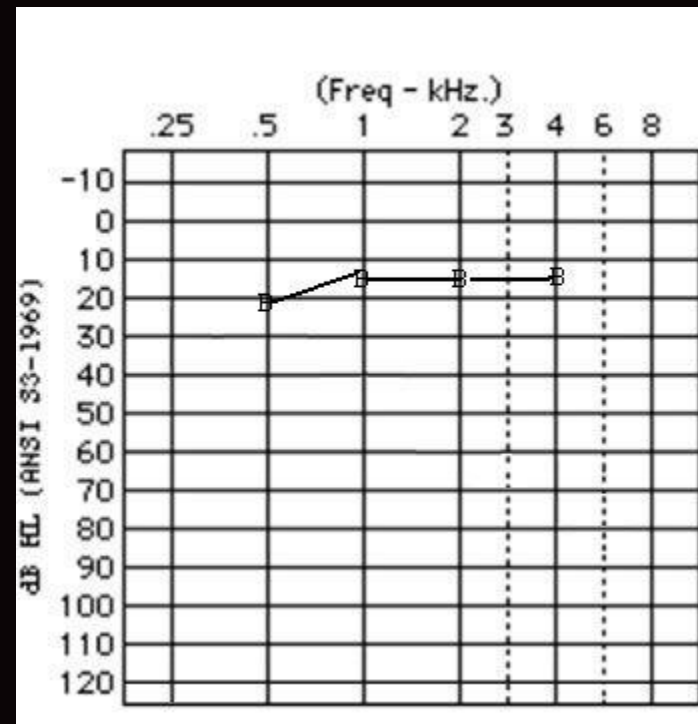
Haven

- DOB 12-1-2006
- Failed NBHS
- Pierre Robin Sequence
- ABR at 3 months 8 days of age confirmed moderate CHL AU
- Fit with loaner Baha at 3 months 20 days of age

Haven

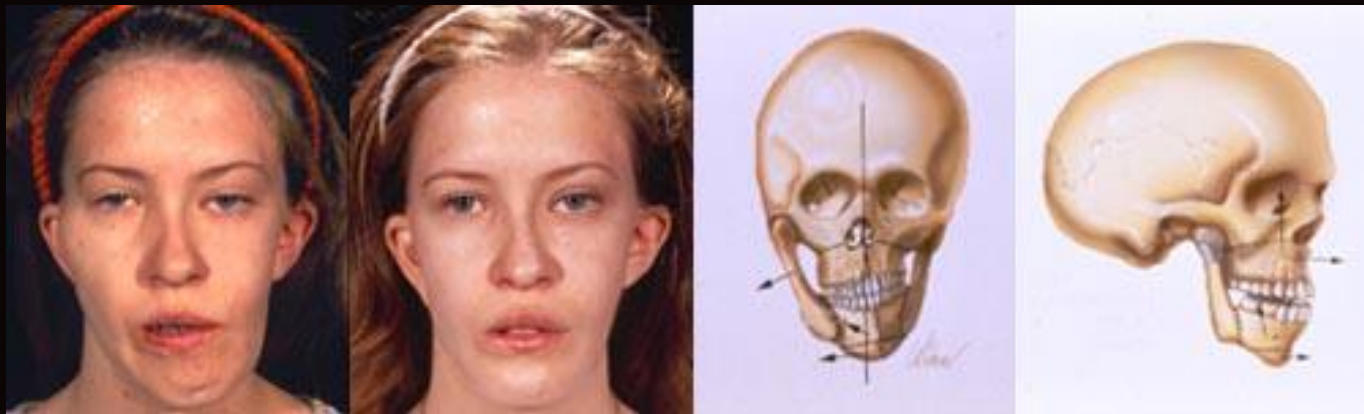

Unaided



Aided

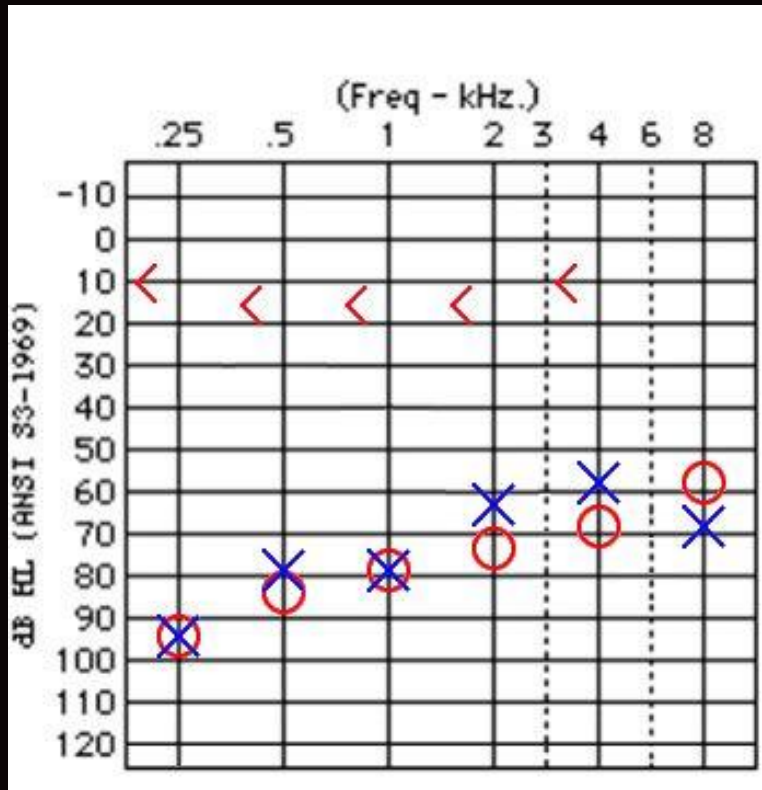
Goldenahar's Syndrome



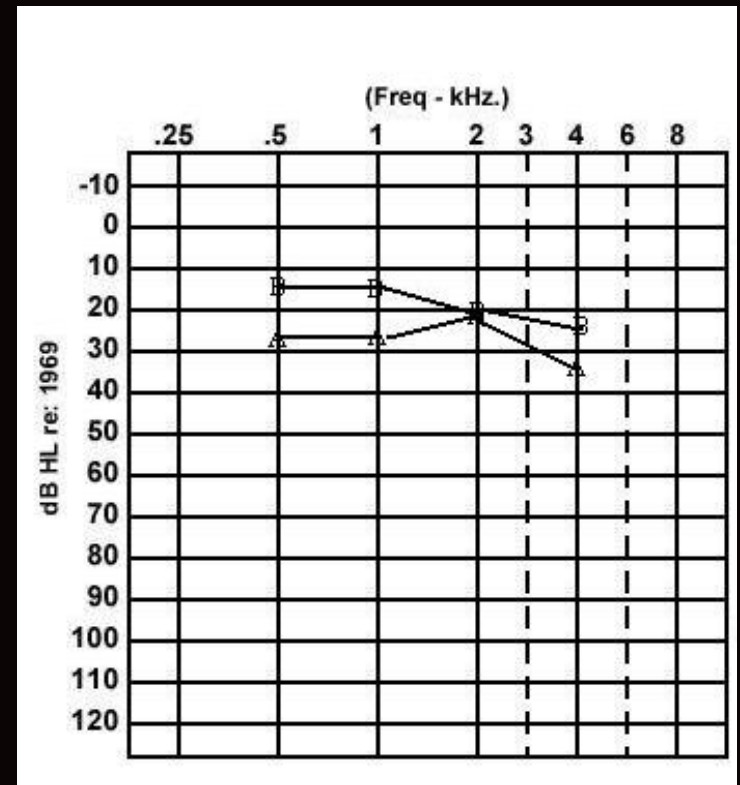
Miracle

- DOB: 6-28-1996
- Goldenhar Syndrome
- Wore conventional BC aid until 10-2006
- Several outer ear reconstructions – all unsuccessful
- Traditional BC aid gave her headaches daily
- Her Dream: To wear earrings and loose her headband.

Miracle



Unaided



Aided Traditional BC vs. Baha Softband

Couryion

- ACH NICU
- Di George Syndrome
- Bilateral atresia
- ENT resident called in Baha loaner
- ABR first!
- No response ABR to BC or AC
- No VIII nerve

Sara

- DOB: 11-21-2006
- No non-users
- Mother has TCS
- Sara has TCS
- Mother wears conventional BC aid
- Sara has a Baha in her possession
- My attempts
 - AV therapist
 - Tested mother and Sara
 - Toys R Us

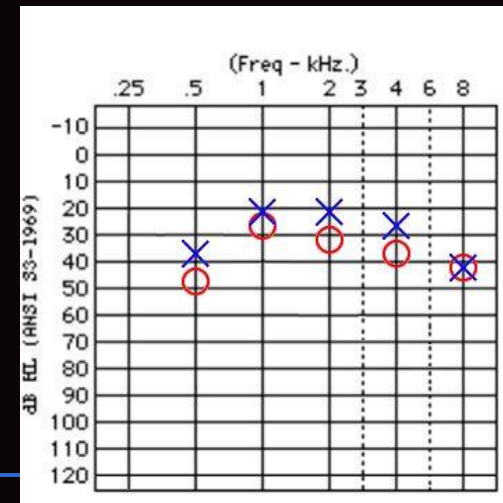
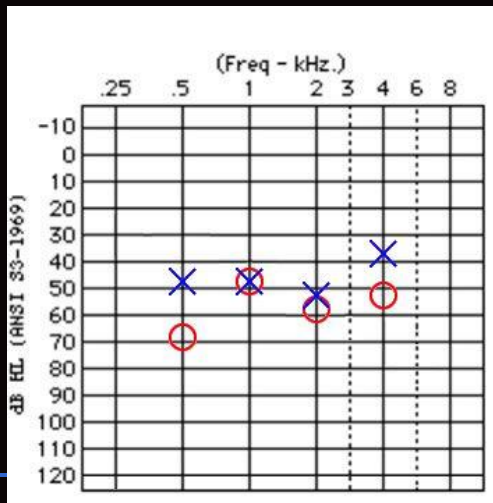
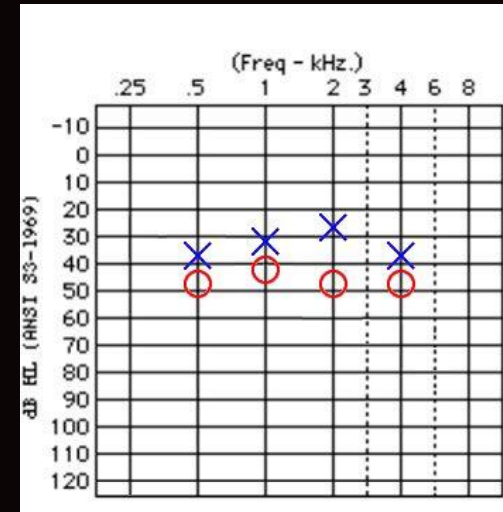
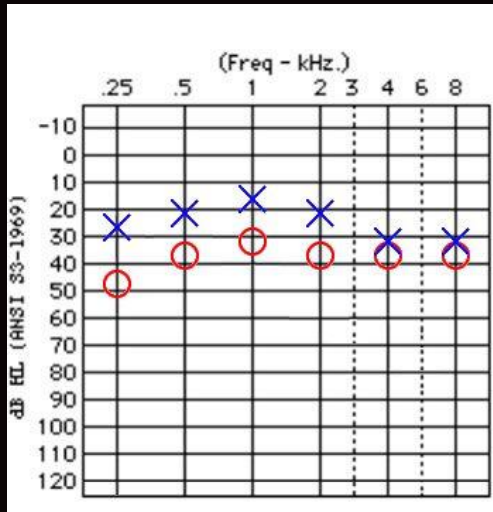
Down's Syndrome



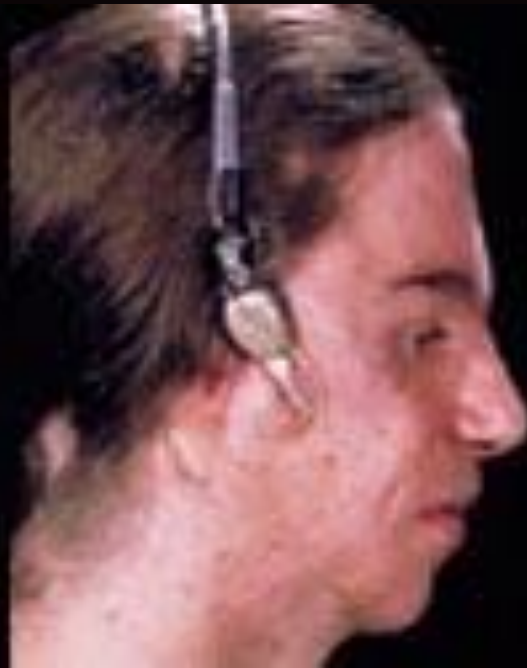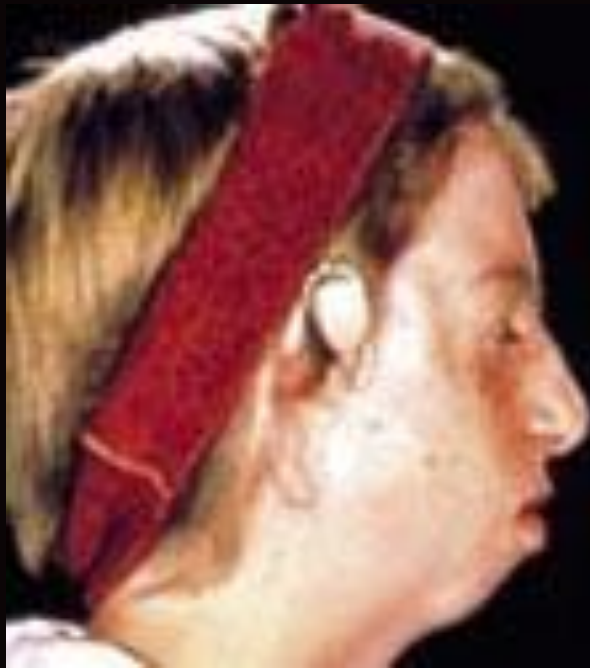Oriana

- DOB: 5-12-1998
- Down Syndrome
- COM
- PET placed and CHL remained
- Great-grandparents concerned about hearing
- Fit with Baha on Softband 10-11-2006

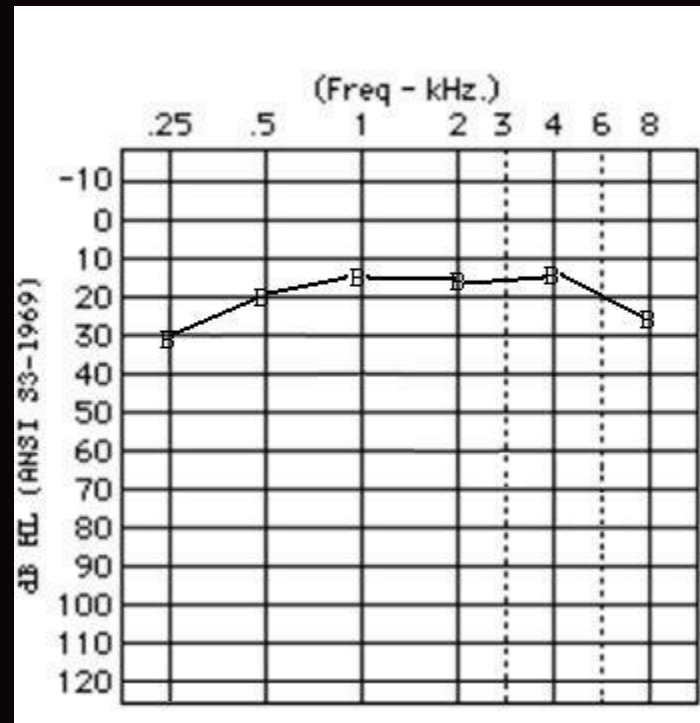
Oriana...ever changing...



Treacher-Collins Syndrome



Oriana

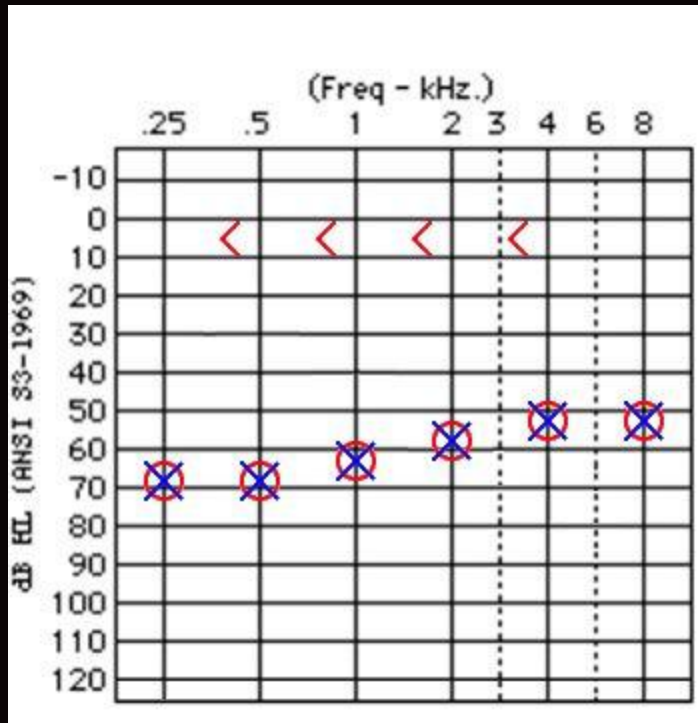


Aided with Baha Softband

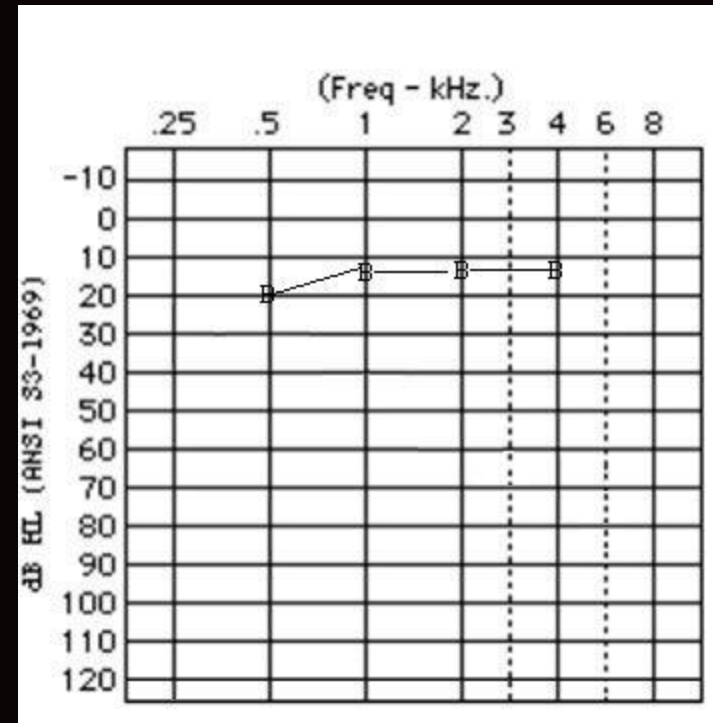
Cason

- DOB: 4-30-2004
- Failed NBHS
- Normal pinnae
- Bony wall atresia
- Re-screen 5-26-2004
- ENT and ABR 7-6-2004
- Fit with Baha loaner on 7-13-2004

Cason



Unaided



Aided Softband